

# Planned pregnancy termination and secondary hysterectomy at 15 weeks for fetal anomaly in a previously untreated Uterine Arteriovenous Malformation

## A case report

Mizar Paragona<sup>1</sup>, Federica Brosio<sup>1</sup>, Pascale Riu<sup>2</sup>, Giovanna Scassellati Sforzolini<sup>1</sup>

<sup>1</sup>Department of Obstetrics and Gynaecology, San Camillo Forlanini Hospital, Rome, Italy <sup>2</sup>Department of Cardiological Science, San Camillo Forlanini Hospital, Rome, Italy

### ABSTRACT

**BACKGROUND.** uterine arteriovenous malformation (AVM) is a rare finding, typically evolving over time. Hormonal changes or trauma often stimulate its evolution. Pregnancy and related surgical procedures are two important evolving factors.

**CASE.** A 37 years old woman gravida 3-para 0, had to terminate her third pregnancy due to a fetal anomaly at 14 weeks and 5 days of gestation in 2013. In 2009 after a vaginal bleeding, RMN and TC had diagnosed an uterine AVM. She had previously received two dilatations and curettage for \*spontaneous abortions and an operative hysteroscopy for septate uterus. Preoperative arterial selective embolization was performed, in order to avoid excessive blood loss during termination and a hysterectomy was performed according to patient's desire to avoid major complications and new pregnancy.

**CONCLUSION.** Fertile patient women affected by AVM should receive appropriate counseling and, treatment, when requested by the woman, should be envisioned before new conception.

### RIASSUNTO

**ANTEFATTO.** Le malformazioni arterovenose (MAV) dell'utero sono reperti rari, che tipicamente progrediscono nel tempo. Modificazioni ormonali o traumatismi locali spesso inducono e stimolano l'evoluzione di tali lesioni. La gravidanza e le procedure chirurgiche ad essa collegate rappresentano due importanti fattori scatenanti.

**CASO CLINICO.** Nel 2013 una donna di 37 anni gravida 3, para 0, si trovò costretta ad interrompere la sua terza gravidanza per un severa anomalia fetale a 14 settimane + 5 giorni. Nel 2009 in occasione di un imponente evento meno-metrorragico, le era stata diagnosticata una malformazione arterovenosa dell'utero, tramite Risonanza Magnetica (RM) e Tomografia Assiale Computerizzata (TC). In precedenza la paziente era stata sottoposta a due isterosuzioni seguite da revisione della cavità uterina e ad una metroplastica isteroscopica per utero setto. Prima di procedere all'intervento è stata effettuata un'embolizzazione selettiva per limitare le perdite ematiche durante la procedura di interruzione e l'isterectomia programmata, in accordo con la paziente per evitare successive e più gravi complicanze in occasione di ulteriori gravidanze.

**CONCLUSIONI.** Al momento della diagnosi di una MAV uterina, le pazienti in età fertile dovrebbero ricevere un adeguato counseling ed un appropriato trattamento prima di rimanere nuovamente in stato di gravidanza.

Key-words: Uterine Arteriovenous Malformation - Pregnancy - Selective Embolization

Parole chiave: Malformazione Arterovenosa Uterina - Gravidanza - Embolizzazione Selettiva

### INTRODUCTION

Uterine Arteriovenous Malformations (AVM) may be either congenital or acquired. Congenital AVM are very sporadic, but some mutations have been identified in systemic vascular malformations syndrome, such as Hereditary Hemorrhagic Telangiectasia (ALK-1 and endoglin)<sup>(1,2,3)</sup>. Acquired AVM are usually post instrumental such as diagnostic curettage or curettage for abortion or post partum

procedures, caesarian delivery, surgical trauma but also are linked to gestational trophoblastic disease, diethylstilbestrol exposure, endometrial, cervical cancer and conservative procedures such as embolization for placenta percreta<sup>(4,5,6)</sup>. An AVM consists of supplying arteries bypassing the capillary bed and draining veins. Typically lesions start with minimal shunting but time and traumatic or hormonal stimulation make it evolve to active shunting with venous engorgement and venous hypertension. Extensive vaginal bleeding with negative beta-H CGC along with a history of any uterine instrumentation are strongly evocative of a uterine AVM. Also post partum or

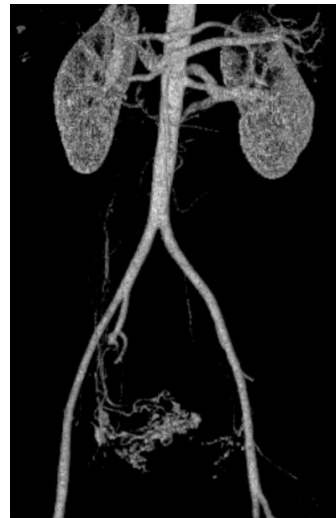Correspondence to: Mizar Paragona  
mizarparagona@libero.it  
Copyright 2014, Partner-Graf srl, Prato

post abortion hemorrhages, typically worsened by curettage, could be signs of a hidden uterine AVM. Trans-vaginal color Doppler US shows dilated vascular channels within the myometrium characterized by high velocity, low resistance and multidirectional flow. MR and TC can show these vascular anomalies perfectly. MR angiography and angio-TC with 3D reconstructions are useful in demonstrating the extension and vascular anatomy of the lesions<sup>(7)</sup>. As angiography has been the gold standard for the diagnosis of AVM for a long time, this procedure now has to be considered as the first step of a therapeutic embolization, avoiding two endovascular approaches. Embolization has gained increasing acceptance as first line treatment option, and is preferred to more invasive solutions like selective uterine artery ligation or hysterectomy. Also expectant management or medical therapies are available alternatives. Management of uterine AVM should be individualized, depending on hemodynamic stability and the patient's desire to preserve fertility. This report describes complications which occurred in a pregnant woman with a previously diagnosed untreated symptomatic uterine AVM.

## CASE REPORT

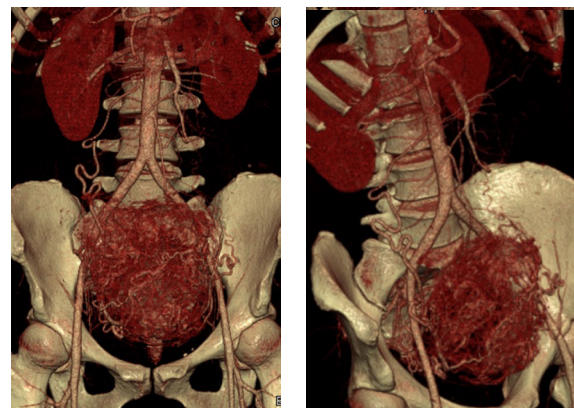
In February 2013, a 37 years old woman, gravida 3-para 0 had to terminate her pregnancy for an serious fetal malformation diagnosed at the end of the first trimester. In 2002 and 2004 she had received two dilations and curettage for spontaneous abortions. In September 2008, an operative hysteroscopy was carried out to treat her septate uterus. In December 2008, the patient was hospitalized for two days in an intensive care unit, for massive menorrhagia, requiring uterine tamponade, bladder catheterization with compressive balloon and blood transfusions. As ultrasonography showed vascular malformation of myometrium, medical therapy with Gn-RH analogues was started.

An MRI and a CT in February and September 2009 confirmed the diagnosis, showing a vascular arteriovenous malformation within the right, anterior and fundic myometrial wall, reaching the endometrium and involving ipsilateral uterine vessels (Figure 1). In November 2012, she spontaneously achieved a twin pregnancy. Since uterine AVM was still present, the mother was counseled about risks related to both pregnancy and delivery. Initially, she wanted to go on with pregnancy but first one twin vanished and then a large omphalocele was found in the surviving



**Figure 1.**  
3D-angio CT reconstruction of an performed in 2009 in non-pregnant condition, shows uterine AVM originating from the right uterine and ovary arteries.

fetus, at 13 weeks of gestation. Angio-CT was repeated showing evolution of uterine AVM (Figure 2). Before terminating pregnancy, after informed consent was obtained, angiographic selective catheterization and embolization of the right ovarian artery and the right uterine artery was performed in order to avoid hemorrhagic complication during surgical procedures. A large vascular anomaly was seen during caesarean delivery in right large ligament. As previously planned with the patient, after fetal and placental removal, a subtotal hysterectomy, with conservation of both, andrea was performed. Histological examination of the uterus showed chorionic villi deeply cleaving the right uterine wall near the tubal ostium and numerous vessels in the right myometrium and surrounding tissues. Placenta was characterized by maturational and morphostructural changes. Autopsy confirmed severe fetal malformation.



**Figures 2a-b.**  
3D-angioCT reconstruction at the 14th week of gestation in the same patient shows the evolution of the uterine AVM and typical vascularization in pregnant condition.

## DISCUSSION

Uterine AVM's true incidence is unknown. These rare vascular anomalies have been reported in both adolescence and in menopause, but they predominantly occur in women of reproductive age. As in the present case, its most frequent clinical presentation is menorrhagia or menometrorrhagia, requiring blood transfusion in 30% of reported cases<sup>(8)</sup>.

Curettage is the most frequent cause of an acquired uterine AVM, even if any uterine trauma could lead to this pathology. In particular, in the present case, operative hysteroscopy could induce AVM since inset of menorrhagia was reported two months after hysteroscopic procedure.

To date, few cases of uterine AVMs in pregnant women have been described.

Most of these were related to primary or secondary post-partum hemorrhages, either from term deliveries<sup>(9,10,11, 12)</sup>, or after procedures for second trimester termination of pregnancies<sup>(13, 14)</sup>.

Also massive uterine bleeding at 8 gestational weeks, requiring hysterectomy with bilateral salpingo-oophorectomy has been described<sup>(15)</sup>.

In 1995 Simpson reported an acute abdomen secondary to a rupture of a uterine AVM in the peritoneal cavity, with severe fetal distress at 38 weeks. Both mother and neonate survived<sup>(16)</sup>.

A recurrence of a previously treated uterine AVM was reported in a pregnancy with pre-term labor and forceps vaginal delivery of a healthy child at 34 weeks of gestation<sup>(17)</sup>.

In two cases of uterine AVMs, one congenital<sup>(3)</sup> and the other acquired<sup>(18)</sup>, conservative management of pregnancy ended in both good fetal and maternal outcomes.

One bilateral uterine artery embolization, during an ongoing pregnancy of 20 weeks of gestation has been described. At 35 weeks a repeat cesarean delivery was performed without any complications<sup>(19)</sup>.

Although literature suggests that Uterine

AVMs' behavior is unpredictable during pregnancy, potentially life-threatening conditions are frequently reported. The hormonal changes during pregnancy seem to make the lesion evolve<sup>(20)</sup>. Therefore when diagnosed, spontaneous or therapeutic resolution of the lesion is advocated before pregnancy.

In our case, placentation was strictly connected to vascular lesion, as shown by histological examination. This could represent a negative prognosis factor for uterine AVM evolution during gestation and for failure of conservative management. Castro et al, in their case report described "always normal myometrium between the AVM and placenta".

If diagnosed in asymptomatic women, uterine AVM resolves spontaneously in a high percentage of cases, so in stable women, especially if asymptomatic, expectant management may have a role<sup>(21)</sup>.

If bleeding is not severe, long term medical management with methylergonovine, estrogen and progestin or Gn-RH agonist<sup>(22)</sup>, could stop the bleeding and make the AVM disappear, with possible subsequent pregnancies<sup>(23, 24, 25)</sup>.

In the presence of recurrent or severe bleedings, or instable hemodynamic conditions, angiographic arterial embolization is currently the treatment of choice, with several cases of successful deliveries<sup>(26, 27, 28, 29, 30, 31, 32)</sup>.

In the present case, after acute treatment in December 2008, medical therapy with Gn-RH analogues stopped bleedings, but did not induce regression of AVM. Also three years of expectant management did not work. This lesion most probably worsened during this pregnancy, as at its beginning in November 2012, it was certainly present. Considering the motherhood desire of this woman, even in the absence of clinical manifestations, an angiographic selective embolization before pregnancy should have been attempted.

## REFERENCES

- 1) Guttmacher AE, Marchuk DA, White RI. **Hereditary hemorrhagic telangiectasia.** N Engl J Med. 1995; 333: 918-24
- 2) Bourdeux A, Cymerman U, Paquet ME, et al **Endoglin expression is reduced in normal vessels but still detectable in arteriovenous malformation of patient with hemorrhagic telangiectasia type 1.** Am J Pathol. 2000; 156(3): 911-23
- 3) Dahlgren LS, Effer SB, McGillivray BC, et al. **Pregnancy with uterine vascular malformation associated with hemorrhagic hereditary telangiectasia: a case report.** J Obstet Gynecol Can. 2006; 28(8): 720-3
- 4) Peitsidis P, Manolagos E, Tsekoura V, et al. **Uterine arteriovenous malformations induced after diagnostic curettage: a systematic review.** Arch Gynecol Obstet. 2011 Nov;284(5):1137-51

- 5) Vandenbroucke L, Morcel K, Bruneau B, et al. **Acquired uterine arteriovenous malformations.** *Gynecol Obstet Fertil.* 2011 Jul-Aug;39(7-8):469-72
- 6) Barber JT Jr, Tressler TB, Willis GS, et al. **Arteriovenous malformation identification after conservative management of placenta percreta with uterine artery embolization and adjunctive therapy.** *Am J Obstet Gynecol.* 2011 May;204(5): 4-8
- 7) Diaz Candamio MJ, Lee VS, Rofsky NM, et al. **Pelvic arteriovenous malformation: gadolinium enhanced three dimensional MR angiography findings.** *Eur Radiol* 2000; 10(8): 171-8
- 8) Huang MW, Murdali D Thurston WA, et al. **Uterine arteriovenous malformation: gray-scale and Doppler features with MR imaging correlation.** *Radiology* 1998; 206: 115-23
- 9) Chien SC, Tseng SC, Hwa HL, et al. **Immediate post-partum haemorrhage caused by rupture of uterine arteriovenous malformation.** *Aust N Z J Obstet Gynaecol.* 2007 Jun;47(3):252-4
- 10) Nasu K, Yamaguchi M, Yoshimatsu J, et al. **Pregnancy complicated by asymptomatic uterine arteriovenous malformation: a case report.** *J Reprod Med.* 2007 Apr;52(4):335-7
- 11) Kelly SM, Belli AM, Campbell S. **Arteriovenous malformation of the uterus associated with secondary postpartum hemorrhage.** *Ultrasound Obstet Gynecol.* 2003 Jun;21(6):602-5
- 12) Uchide K, Suzuki N, Murakami K, Terada S, Inoue M. **Uterine arteriovenous malformation as a cause of immediate postpartum hemorrhage.** *Acta Obstet Gynecol Scand.* 1998 May;77(5):577-80
- 13) Lin AC, Hung YC, Huang LC, et al. **Successful treatment of uterine arteriovenous malformation with percutaneous embolization.** *Taiwan J Obstet Gynecol.* 2007 Mar;46(1):60-3
- 14) Elia G, Counsell C, Singer SJ. **Uterine artery malformation as a hidden cause of severe uterine bleeding. A case report.** *J Reprod Med.* 2001 Apr;46(4):398-400
- 15) Majmudar B, Ghane N, Horowitz IR, et al. **Uterine arteriovenous malformation necessitating hysterectomy with bilateral salpingo-oophorectomy in a young pregnant patient.** *Arch Pathol Lab Med.* 1998 Sep;122(9):842-5
- 16) Simpson I, Ng A, Griffin C. **A rare cause of an acute abdomen in late pregnancy.** *Aust N Z J Obstet Gynaecol.* 1995 Nov;35(4):435-6
- 17) Kelly FW. **Forceps delivery after molar malignancy in a woman with arteriovenous malformation. A case report.** *J Reprod Med.* 2001 Nov;46(11):1013-6
- 18) Castro-Aragon I, Aragon I, Urcuyo R, et al. **Conservative management of a uterine arteriovenous malformation diagnosed in pregnancy.** *J Ultrasound Med.* 2004 Aug;23(8):1101-4; quiz 1105-6
- 19) Rebarber A, Fox NS, Eckstein DA, et al. **Successful bilateral uterine artery embolization during an ongoing pregnancy.** *Obstet Gynecol.* 2009 Feb;113(2 Pt 2):554-6
- 20) Hoffman MK, Meilstrup JW, Shackelford DP, Kaminski PF. **Arteriovenous malformations of the uterus: an uncommon cause of vaginal bleeding.** *Obstet Gynecol Surv.* 1997;52:736-740
- 21) Timmerman D, Van den Bosch T, Peeraer K, et al. **Vascular malformations in the uterus; ultrasonographic diagnosis and conservative management.** *Eur J Obstet Gynecol Reprod Biol.* 2000;92:171-8
- 22) Morikawa M, Yamada T, Yamada H, et al. **Effect of gonadotropin-releasing hormone agonist on a uterine arteriovenous malformation.** *Obstet Gynecol.* 2006 Sep;108(3 Pt 2):751-3
- 23) Nonaka T, Yahata T, Kashima K, et al. **Resolution of uterine arteriovenous malformation and successful pregnancy after treatment with a gonadotropin-releasing hormone agonist.** *Obstet Gynecol.* 2011 Feb;117(2 Pt 2):452-5
- 24) Onoyama I, Fukuhara M, Okuma A, et al. **Successful pregnancy after the noninvasive management of uterine arteriovenous malformation.** *Acta Obstet Gynecol Scand.* 2001 Dec;80(12):1148-9
- 25) Goldberg RP, Flynn MK. **Pregnancy after medical management of a uterine arteriovenous malformation. A case report.** *J Reprod Med.* 2000 Nov;45(11):961-3
- 26) Tsai CC, Cheng YF, Changchien CC, et al. **Successful term pregnancy after selective embolization of a large postmolar uterine arteriovenous malformation.** *Int J Gynecol Cancer.* 2006 Jan-Feb;16 Suppl 1:439-41
- 27) McCormick CC, Kim HS. **Successful pregnancy with a full-term vaginal delivery one year after n-butyl cyanoacrylate embolization of a uterine arteriovenous malformation.** *Cardiovasc Intervent Radiol.* 2006 Jul-Aug;29(4):699-701
- 28) Delotte J, Chevallier P, Benoit B, et al. **Pregnancy after embolization therapy for uterine arteriovenous malformation.** *Fertil Steril.* 2006 Jan;85(1):228
- 29) Nikolopoulos G, Murray A. **Successful pregnancy outcome after surgical removal of arteriovenous malformation of the uterus.** *J Obstet Gynaecol.* 2004 Apr;24(3):315-6
- 30) Gopal M, Goldberg J, Klein TA, et al. **Embolization of a uterine arteriovenous malformation followed by a twin pregnancy.** *Obstet Gynecol.* 2003 Oct;102(4):696-8
- 31) Garner EI, Meyerovitz M, Goldstein DP, et al. **Successful term pregnancy after selective arterial embolization of symptomatic arteriovenous malformation in the setting of gestational trophoblastic tumor.** *Gynecol Oncol.* 2003 Jan;88(1):69-72
- 32) Arredondo-Soberon F, Loret de Mola JR, et al. **Uterine arteriovenous malformation in a patient with recurrent pregnancy loss and a bicornuate uterus. A case report.** *J Reprod Med.* 1997 Apr; 42(4):239-43