



Robotic aortic lymphadenectomy during multi-quadrant surgery for gynecological cancers with the new “Da Vinci Xi” system

Mariano C. Di Donna¹, Alessandro Lucidi³, Valerio Gallotta², Giulio Sozzi¹, Francesco Fanfani², Marco Petrillo⁴, Giuseppe Vizzielli², Anna Fagotti², Vito Chiantera¹, Giovanni Scambia²

¹Division of Gynecologic Oncology, University of Palermo, Palermo, Italy.

²Gynecologic Oncologic Unit, Catholic University of the Sacred Heart, Rome, Italy.

³Gynecologic Oncologic Unit, Hospital G. Bernabeo, Ortona (Chieti), Università G. D'Annunzio, Ortona (Chieti), Italy.

⁴Obstetric and Gynecology Unit, University of Sassari, Sassari, Italy.

ABSTRACT

Objective: The aim of this study is to report the feasibility and safety of robotic para-aortic lymphadenectomy (PAL) during multi-quadrant surgery for gynecological malignancies with the new Da Vinci Xi system.

Methods: Prospective study of Da Vinci Xi PAL in a series of 21 gynecological malignancies between October-March 2014-2015. Patients received PAL during surgery without repositioning the robot. Of the whole group: 4 patients received PAL for endometrial cancer; 8 for cervical cancer and 9 for ovarian cancer.

Results: Operative time, Robotic rotation time, estimated blood loss and median number of removed lymph nodes were recorded. Median rotation time and median aortic time was 3 minutes (range: 2-4) and 69 minutes (range: 40-110) respectively. Median number of aortic nodes removed was 13 (range 7-21). Conversion rate was 19%, median length of hospital stay was 3 days. There were no mortalities.

Conclusion: Robotic PAL without repositioning with the new Da Vinci Xi System results both safe and feasible. Further randomized trials are needed to determine whether the Da Vinci Xi System truly offers any advantages in terms of oncological outcome or long-term results.

Keywords: robotic surgery; aortic lymphadenectomy; gynecological cancer.

SOMMARIO

Obiettivo: Lo scopo di questo studio è quello di valutare la fattibilità e la sicurezza della linfadenectomia paraortica robotica (PAL) durante la chirurgia multi-quadrante per neoplasie ginecologiche con il nuovo sistema Da Vinci Xi.

Metodi: È uno studio prospettico che valuta la PAL eseguita con il sistema Da Vinci Xi in una serie di 21 neoplasie ginecologiche tra ottobre-marzo 2014-2015. Le pazienti hanno ricevuto una PAL durante l'intervento chirurgico senza riposizionamento del robot. Di tutto il gruppo: 4 pazienti hanno ricevuto PAL per neoplasia dell'endometrio; 8 per neoplasia cervicale e 9 per neoplasia ovarica.

Risultati: Sono stati registrati il tempo chirurgico, il tempo di rotazione robotica, la perdita ematica stimata e il numero medio di linfonodi rimossi. Il tempo medio di rotazione e il tempo medio per l'esecuzione della linfadenectomia aortica è stato rispettivamente di 3 minuti (range: 2-4) e 69 minuti (range: 40-110). Il numero medio di linfonodi aortici rimossi è stato di 13 (range 7-21). Il tasso di conversione è stato del 19%, la durata media della degenza ospedaliera è stata di 3 giorni. Non è stata registrata mortalità.

Conclusioni: La PAL robotica senza riposizionamento del robot con il nuovo sistema Da Vinci Xi risulta fattibile e sicura. Ulteriori studi randomizzati sono necessari per determinare se il sistema Da Vinci Xi offre veramente vantaggi in termini di esito oncologico e/o risultati a lungo termine.

Corresponding Author: Mariano Catello Di Donna
marianocatellodidonna@gmail.com

Copyright 2019, Partner-Graf srl, Prato

DOI: 10.14660/2385-0868-109

INTRODUCTION

Paraaortic lymphadenectomy (PAL) is a cornerstone therapeutic strategy in the management of gynecologic malignancies for advanced stage of cervical cancer, high-risk endometrial cancer, early stage ovarian staging and localized relapses.

Laparoscopic para-aortic node dissection has been shown to be feasible in gynecological malignancies with lower morbidity than traditional laparotomy^(1,4).

Since its approbation in 2005 the Da Vinci robotic system has widely gained consensus as surgical tool in complex gynecological operations.

This system provides instruments with a wrist function at the tip, movement downgrading, tremor elimination, a stable 3-dimension view of the operative field and an ergonomic working position; in addition the surgeon does not have to struggle with the weight of a thick abdominal wall⁽⁵⁾. These features may theoretically help the surgeon overcome some of the difficulties associated with traditional laparoscopic surgery. The new Xi is an improvement of the previous version Si system: the docking is simpler and is designed to be user friendly guided by a "port placement menu". The laparoscope has a digital end mounted camera for improved vision and requires no draping. The scope can be placed into any of the robotic arms and has the autofocus. Because of the improved design for the arms, the ports can be placed relatively close together and still avoid collision. Finally, the most impressive feature is the ability of the robot to work effectively in multiple quadrants without needs of

re-positioning. We report in this manuscript the first series of aortic lymphadenectomy performed with the new robotic system during multi-quadrant surgery for gynecological malignancies with a "single robotic position setting".

MATERIALS AND METHODS

This is a prospective study, analyzing peri-operative outcomes of Da Vinci Xi PAL in a series of 21 gynecological cancer patients. Cases have been operated at the Gynecologic Oncologic Unit, Catholic University of the Sacred Heart, Rome, Italy, between October 2014 and March 2015. Clinical-pathological characteristics of the patients are shown in **Table 1**. Women were informed and signed a written informed consent. As part of the data collection, the following variables were prospectively recorded: age, histology, surgical type, lymph node assessment, BMI, prior abdominal surgery, operative and postoperative complications, length of hospital stay, estimated blood loss, operation time (OT), robotic rotation time (RT) and aortic operative time (AOT). Prior abdominal surgery included any surgical intervention into the abdomen, whether or not it was performed via laparotomy. The OT includes the docking time and the intra-abdominal operating time until the last surgical suture stich positioning. The RT includes the time required for the robotic arm rotation from the pelvic configuration to the upper

Table 1.
Patient characteristics.

Variable	LND Aortic Da Vinci-Xi
All cases	21
Median Age (range)	52 (30 - 74)
Median BMI (range)	25 (19 - 39)
Previous abdominal surgery	
Yes	8 (38.1)
No	13 (61.9)
Diagnosis	
Endometrial cancer	4 (19.0)
Cervical cancer	8 (38.1)
Ovarian cancer	9 (42.9)
Aortic Lymph-node assessment	
Positive	6 (28.6)
Negative	15 (71.4)
Median number of lymph-nodes (range)	13 (7-21)

abdominal configuration used for aortic infra-renal lymphadenectomy. The AOT represents the time we need for aortic lymphadenectomy. Surgical complications were evaluated using the Dindo-Claiven classification⁽⁶⁾. Post-operative complications were defined as any adverse event occurring within 30 days from surgery, and considered severe if resulted in unplanned re-admission or secondary surgical procedure. All cases required multi-quadrant abdominal surgery, type and numbers of procedure performed for each patient are shown in **Table 2**.

Thanks to the flexibility of the new Da Vinci Xi system a single robotic set-up was used for every multi-quadrant operation despite the numbers of abdominal areas needed to be reached. The robotic system was always placed in a single position on the right side of the patients and the procedures were always started with the robotic pelvic configuration for the lower abdomen. Trocars were placed as showed in **Figure 1**. The ports were placed along the transverse umbilical line with a distance of about 7 cm from each other. The Xi allows to choose different configurations

depending on surgical targets, whether pelvic or in the upper abdomen without repositioning of the robotic column and after the choice of surgical field the robot will automatically place the arms in order to minimize the risk of collisions. When a different quadrant is required a new surgical target is choose and the robot will automatically place its arms using the same trocars despite the new surgical area that needs to be reached. The relocation of the robotic column or the patient's rotation is always not necessary. The instruments placement is the same for both configurations: the grasp forceps is placed in RT1, the monopolar curved scissors in RT2, the fenestrated bipolar forceps in RT4 and the telescope in RT3 (**Figure 1**).

All of paraaortic lymphadenectomies were carried out to the level of the renal veins. The surgical technique used was completely borrowed from our previous laparoscopic experience⁽⁷⁾. First, the right common iliac artery is identified and the retroperitoneum is opened at this level, revealing the right psoas muscle. The peritoneal incision is extended parallel to the aorta up to the Duodenum.

Table 2.
Surgical procedures.

Surgical procedures	LND Aortic Da Vinci-Xi Nr. (%)
Hysterectomy	19 (90)
Unilateral/Bilateral salpingo-oophorectomy	15 (71)
Pelvic lymphadenectomy	18 (86)
Pelvic peritonectomy	3 (14)
Omentectomy	10 (47)

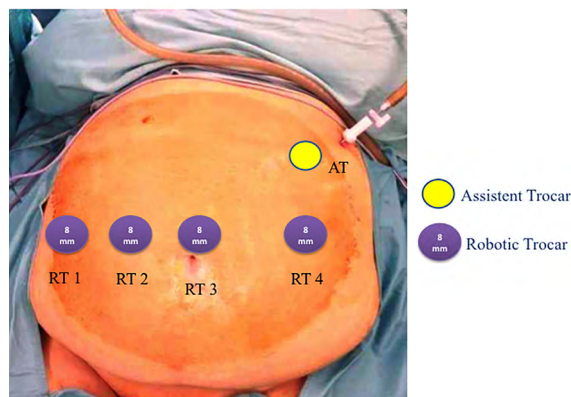


Figure 1.
Instrument placement. the grasp forceps (RT1). The monopolar curved scissors (RT2). The fenestrated bipolar forceps (RT4). Telescope (RT3). Assistant trocar (AT).

A small tent is then created elevating the right peritoneum ventrally with the grasp forceps inserted in the first arm, RT1 (**Figure 1**).

Then, differently from our laparoscopic technique the left peritoneum close to the Treitz ligament is not incised. This reduces the space of the surgical field but prevent the small bowel to fall down from the left side. Still a complete aortic lymphadenectomy is possible thanks to the articulated instruments of the robotic arms and the ability of the system to work even in narrow space.

The right mesocolon is now elevated with the first arm (RT 1; grasp forceps) exposing dorsally the body of the inferior vena cava and laterally the right ureter and the right gonadic vein.

The sigmoid mesentery is retracted laterally with the exposition of the contralateral psoas muscle and the left ureter.

Once the left renal vein is identified the cranial dissection is pushed up to the level of the superior mesenteric artery in order to have a complete control of the renal artery and vein in case of bleeding. The assistant trocar is either used with a laparoscopic surgical retractor to push cranially the Duodenum or Pancreas body or to mobilize the aorta or the inferior vena cava in case ultraradical aortic lymphadenectomy is required.

Para-aortic, intra-aortocaval and para-caval node dissection is performed beginning at the aortic bifurcation progressing to the renal vein, identifying and preserving the inferior mesenteric artery. If necessary retrocaval and retroaortic nodes dissection was performed using the assistant arm either to lift the cava or the aorta (**Figure 2** and **3**).

RESULTS

Between October 2014 and March 2015, 21 patients were treated for Gynecological malignancies at the Catholic University of the Sacred Heart of Rome. All patients received surgical treatment with the Da Vinci Xi System: 4 for endometrial cancer (n= 4; 19%), 8 for cervical cancer (n= 8; 38.1%) and 9 for ovarian

cancer (n= 9; 42.9%). All women underwent multi-quadrant surgery including either pelvic plus aortic or pelvic plus aortic plus sovramesocolic. In all cases infrarenal aortic lymphadenectomy were performed. Conversion rate was 19 % (4 cases): 2 cases required conversion to standard laparotomy for severe obesity. The conversion was necessary for the impossibility to identify the classical anatomical landmarks due to visceral obesity of the patients and therefore to perform the surgical technique safely. While in two other cases conversion was necessary for the presence of aortic bulky nodes. In no cases emergency conversion was required. Peri-operative outcomes are shown in **Table 3**.

The median estimated blood loss was 100 ml (range: 0-350), the median operative time was 300 minutes (range: 100-560) for the whole multi-quadrant procedure. The median robotic rotation time from pelvic to aortic configuration was 3 minutes (range: 2-4). The median operative aortic time was 69 minutes (range: 40-110).

The median discharge time from the hospital was day 3. The median number of removed aortic lymph nodes was 13 (range: 7-21).

There were 1 intra-operative complications: a left renal vein injury which was robotically repaired with no major intervention. No post-operative complications correlated to the aortic procedures were observed.

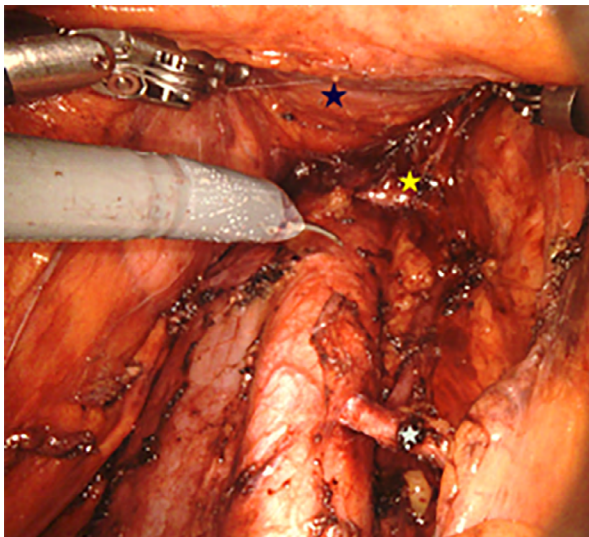


Figure 2.

Para-aortic, intra-aortocaval and para-caval node dissection is performed beginning at the aortic bifurcation progressing to the renal vein, identifying and preserving the inferior mesenteric artery. Duodenum (blue star). Renal vein (yellow star). Mesenteric artery (white star).

Source: Prof. Vito Chiantera. Robotic Surgery, Gynecologic Oncologic Unit, Catholic University of the Sacred Heart, Rome, Italy.

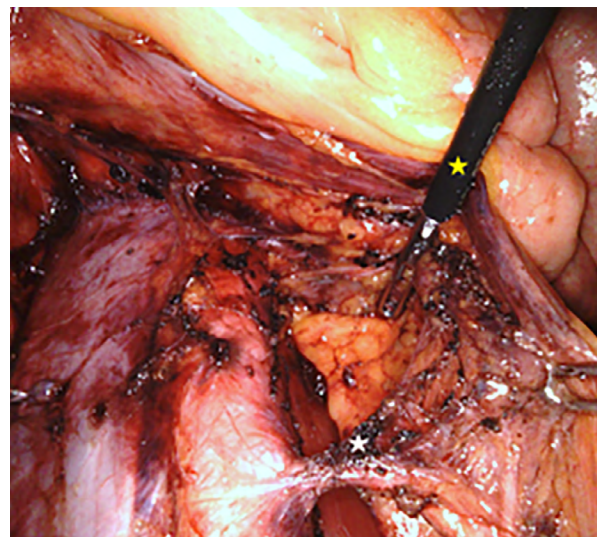


Figure 3.

Retrocaval and retroaortic nodes dissection was performed using the assistant arm (yellow star) either to lift the cava or the aorta. Bland dissection (arrows).

Source: Prof. Vito Chiantera. Robotic Surgery, Gynecologic Oncologic Unit, Catholic University of the Sacred Heart, Rome, Italy.

Table 3.
Perioperative outcomes.

Variable	LND Aortic Da Vinci-Xi
Median operative time (min) (range)	300 (100 - 560)
Median rotation time (min) (range)	3 (2-4)
Median operative aortic time (min) (range)	69 (40-110)
Median estimated blood loss (mL) (range)	100 (0 - 350)
Intra-operative complications	
Yes	1 (4.8)
No	20 (95.2)
Conversion to laparotomy	
Yes	4 (19.0)
No	17 (81.0)
Median day to discharge	3 (2 - 11)

DISCUSSION

The feasibility and safety of robotically assisted PAL during multiquadrant surgery with the previous DaVinci Si surgical system has been already reported but the better surgical strategy is still debated^(8,10). The initial descriptions of robotic-assisted para-aortic lymphadenectomy were trans-peritoneal resection of lymph nodes below the inferior mesenteric artery, using a single center-docked approach^(11,12). Narducci et al.⁽¹³⁾ presented a preliminary report of robotic-assisted laparoscopic extra-peritoneal PAL up to the left renal vein positioning the robotic system at the right shoulder of the patient. This study showed that para-aortic lymphadenectomy up to the left renal vein was feasible but combining pelvic surgery was not possible. For both pelvic and paraaortic node staging Lambaudie et al.⁽¹⁴⁾ proposed a new configuration with a single positioning for the robot, between the patient's legs and the placement of the camera port and the robotic trocars very high in the abdomen. With this technique the exposure of the left renal vein appeared difficult, particularly in case of high BMI, due to both the shortness of the mesentery, and the proximity between the optic and the renal vein placed just beneath the camera port site. In addition, a lower mean number of lymph nodes was observed in this series when compared with patients who had isolated PAL (7.8 versus 14.6). As result was suggested, to increase the mean number of lymph nodes, a rotation of the table or of the robot during surgery. Magrina et al.⁽¹⁵⁾ investigated trans-peritoneal infra-renal aortic lymphadenectomy in the cadaver model and

found exposure of the upper aorta very difficult and limiting. They subsequently developed a "dual-positioning" approach with one robotic docking over the head to accomplish infra-renal aortic lymphadenectomy. The second docking was centered between the legs after rotation of the operative table, allowing completion of the hysterectomy and pelvic lymphadenectomy. With this solution in a study of 33 gynecologic cancer patients who underwent infra-renal lymphadenectomies combined with other procedures including hysterectomy, Magrina et al.⁽⁹⁾ reported removal of 12.9 (range 2-27) aortic lymph nodes. Using a similar dual-positioning technique, Zanagnolo et al.⁽¹⁶⁾ reported infra-renal lymphadenectomy with a mean of 14.0 ± 6.6 aortic nodes removed. As discussed potential disadvantages with the dual-positioning approach include the necessity for additional laparoscopic ports, increased operative time and coordination of the operative team during rotation of the table. A recent study conducted by Franké et al.⁽¹⁷⁾ confirmed a statistical difference between Single docking and Double Docking concerning aortic lymph node count (5.86 vs 10.89, P = 0.005). In addition, operative time was longer in the Double Docking group (326.1 vs 239.4 minutes, P = 0.05). These data confirmed the inability of the Da Vinci Si to provide access to the entire abdomen without relocating the robotic column. Compared to conventional laparoscopy where the surgeon moves around the patient without any constraint to work in the pelvis or in the upper abdomen, the major limitation of the robotic system has

been reported when a combined procedure both in pelvis and in the upper abdomen is necessary. In this context, the new device, da Vinci Xi system should offer the ability to work effectively in multiple quadrants without re-positioning the robotic column. We have reported in this manuscript the first series of aortic lymphadenectomy for gynecological malignancies performed with the new Xi device. Comparing the aortic lymph nodes count and the median aortic operative time with a matched historical series of our aortic infrarenal lymphadenectomy performed with the previous Da Vinci Si system where rotation of the operative table was necessary, no statistical differences was found (Table 4).

For this reason, in our opinion the great advantage of this new device is its ability to work effectively in multiple quadrants without re-positioning. This option could reduce stress of operative team and anesthesiologists. Even more, in our series a consistent number of ovarian cancer patients required more than one upper abdominal surgical procedures and the needs of multiple robotic re-configuration for the upper abdominal surgery and still the median operative time was comparable with previous laparoscopic experiences^(18,19). Although laparoscopic lymphadenectomy is considered feasible and safe, paraortic area, with its potential vessel anomalies

and the frequent significant intra abdominal adhesions, makes the infra-renal area difficult to approach by laparoscopic via. Robotic-assisted surgery more closely imitate open procedures. The tremor elimination, a stable 3-dimension view of the operative field and an ergonomic working position are important advantages for surgeon and makes the approach to this area more feasible and safe. Robotics also reduces the poor ergonomics associated with laparoscopy, particularly during longer procedures⁽²⁰⁾. This last finding confirm how this new robotic system could mirror the ability of the standard laparoscopic surgery to “rotate around the surgical field” in order to achieve always the best surgical approach and visualization. According to Vizza et al. the disadvantages of robotic surgery, which include lack of formal training, and higher costs are barriers to the implementation for robotic surgery in gynecologic oncology⁽²¹⁾. In conclusion, single position robotic paraaortic lymphadenectomy during multiquadrant surgery with the new Da Vinci Xi System results both safe and feasible. Further randomized trials are needed to determine whether the Da Vinci Xi System truly offers any advantages in term of oncological outcome or long-term results compared with previous robotic systems or established laparoscopic surgery.

Table 4.
Da Vinci Si Vs Da Vinci Xi.

Variable	LND Aortic Da Vinci-Si Nr. (%)	LND Aortic Da Vinci-Xi Nr. (%)	p-value
All cases	21 (50)	21 (50)	-
Median Age (range)	53 (24 - 77)	52 (30 - 74)	0.358
Median BMI (range)	27 (19 - 42)	25 (19 - 39)	0.345
Previous abdominal surgery			0.352
Yes	11 (52.4)	8 (38.1)	
No	10 (47.6)	13 (61.9)	
Aortic Lymph-node assessment			0.328
Positive	7 (33.3)	6 (28.6)	
Negative	14 (66.7)	15 (71.4)	
Median number of lymph-nodes (range)	13 (2-35)	13 (7-21)	0.870
Median operative aortic time (min) (range)	63 (46-98)	69 (40-110)	0.312
Median estimated blood loss (mL) (range)	100 (50-800)	100 (0 - 350)	0.615
Intra-operative complications			-
Yes	1 (4.8)	1 (4.8)	
No	20 (95.2)	20 (95.2)	
Conversion to laparotomy			0.830
Yes	3 (14.3)	4 (19.0)	
No	18 (85.7)	17 (81.0)	

DECLARATION OF INTEREST

The Authors declare to have no conflict of interest.

The procedures followed were in accordance with the ethical standards of the Committee on

human experimentation.

The procedures followed application of the standards on patient informed consent.

REFERENCES

- 1) Possover M, Krause N, Plaul K, Kuhne-Heid R, Schneider A. **Laparoscopic para-aortic and pelvic lymphadenectomy: experience with 150 patients and review of the literature.** *Gynecol Oncol* 1998; 71(1): 19–28.
- 2) Querleu D. **Laparoscopic paraaortic node sampling in gynecologic oncology: a preliminary experience.** *Gynecol Oncol* 1993; 49(1):24–9.
- 3) Vergote I, Amant F, Beterloot P, Van Gramberen M. **Laparoscopic lower para-aortic staging lymphadenectomy in stage IB2, II, and III cervical cancer.** *Int J Gynecol Cancer* 2002; 12:22–6.
- 4) Marnitz S, Köhler C, Affonso RJ, Schneider A, Chiantera V, Tsounoda A, Vercellino F. **Validity of laparoscopic staging to avoid adjuvant chemoradiation following radical surgery in patients with early cervical cancer.** *Oncology* 2012;83(6):346–53
- 5) Corrado G, Chiantera V, Fanfani F, Cutillo G, Lucidi A, Mancini E, Pedone Anchora L, Scambia G, Vizza E. **Robotic Hysterectomy in Severely Obese Patients With Endometrial Cancer: A Multicenter Study.** *J Minim Invasive Gynecol.* 2016 Jan 1;23(1):94–100.
- 6) Dindo D, Demartines N, Clavien P-A. **Classification of surgical complications: a new proposal with evaluation in a cohort of 6336 patients and results of a survey.** *Ann Surg.* 2004;240:205–213.
- 7) Gallotta V, Nero C, Chiantera V, Scambia G. **Minilaparoscopic aortic lymphadenectomy.** *J Minim Invasive Gynecol.* 2015 May-Jun;22(4):546–7.
- 8) E. Lambaudie, F. Narducci, E. Leblanc et al., **“Robotically assisted laparoscopy for paraaortic lymphadenectomy: technical description and results of an initial experience”**, *Surgical Endoscopy*, vol. 26, no. 9, pp. 2430–2435, 2012.
- 9) J. F. Magrina, J. B. Long, R. M. Kho, D. L. Giles et al. **“Robotic transperitoneal infrarenal aortic lymphadenectomy technique and results”** *International Journal of Gynecological Cancer*, vol. 20, no. 1, pp. 184–187, 2010.
- 10) Holloway RW, Patel SD, Ahmad S. **Robotic surgery in gynecology.** *Scand J Surg.* 2009;98: 96–109.
- 11) Shafer A, Boggess JF. **Robotic-assisted endometrial cancer staging and radical hysterectomy with the da Vinci surgical system.** *Gynecol Oncol* 2008;111(Suppl. 2):S18–23.
- 12) Vergotte I, Pouseele B, Grp Van, et al. **Robotic retroperitoneal lower para-aortic lymphadenectomy in cervical cancer: first report on the technique used in 5 patients.** *Acta Obstet Gynecol Scand* 2008;87:783–8.
- 13) Narducci F, Lambaudie E, Houvenaeghel G, Collinet P, Leblanc E. **Early experience of robotic-assisted laparoscopy for extraperitoneal para-aortic lymphadenectomy up to the left renal vein.** *Gynecol Oncol.* 2009 Oct;115(1):172–4.
- 14) Lambaudie E, Narducci F, Leblanc E et al. **Robotically assisted laparoscopy for paraaortic lymphadenectomy: technical description and results of an initial experience.** *Surg Endosc.* 2012Sep;26(9):2430–5.
- 15) Magrina JF, Kho R, Montero RP, Magtibay PM, Pawlina W. **Robotic extraperitoneal aortic lymphadenectomy: development of a technique.** *Gynecol Oncol* 2009;113: 32–5.
- 16) Zanagnolo V, Rollo D, Tomaselli T et al. **Robotic-assisted transperitoneal aortic lymphadenectomy as part of staging procedure for gynaecological malignancies: single institution experience.** *Obstet Gynecol Int.* 2013.
- 17) Franké O, Narducci F, Chereau-Ewald E et al. **Role of a double docking to improve lymph node dissection: when robotically assisted laparoscopy for para-aortic lymphadenectomy is associated to a pelvic procedure.** *Int J Gynecol Cancer.* 2015 Feb;25(2):331–6.
- 18) Gallotta V, Ghezzi F, Vizza E, Chiantera V, Ceccaroni M, Franchi M, Fagotti A, Ercoli A, Fanfani F, Parrino C, Uccella S, Corrado G, Scambia G, Ferrandina G. **Laparoscopic staging of apparent early stage ovarian cancer: results of a large, retrospective, multi-institutional series.** *Gynecol Oncol.* 2014 Dec;135(3):428–34.
- 19) Nezhat FR, Finger TN, Vetere P, Radjabi AR, Vega M, Averbuch L, Khalil S, Altinbas SK, Lax D. **Comparison of perioperative outcomes and complication rates between conventional versus robotic-assisted laparoscopy in the evaluation and management of early, advanced, and recurrent stage ovarian, fallopian tube, and primary peritoneal cancer.** *Int J Gynecol Cancer.* 2014 Mar; 24(3):600–7.
- 20) Lee HJ, Lee YH, Chong GO, Hong DG, Lee YS. **Robotic-assisted Transperitoneal Infrarenal Para-aortic Lymphadenectomy for Gynecological Malignancies: Comparison with a Laparoscopic Approach.** *Anticancer Res.* 2017 Dec;37(12):7087–7093.
- 21) Vizza E, Mancini E, Baiocco E, Vicenzoni C, Patrizi L, Saltari M, Cimino M, Sindico S, Corrado G. **Robotic transperitoneal aortic lymphadenectomy in gynecologic cancer: a new robotic surgical technique and review of the literature.** *Ann Surg Oncol.* 2012 Nov;19(12):3832–8.