



Prediction of Fetal Lung Maturity by Ultrasonic Thalamic Echogenicity and Ossification Centers of Fetal Femur and Tibia

Thikra N. Abdulla¹, Qays A. Hassan², Batwl A. Ameen³

¹Department of Obstetrics & Gynecology, Al-Kindy College of Medicine, University of Baghdad. Baghdad, Iraq.

²Division of Radiology, Department of Surgery, Al-Kindy College of Medicine, University of Baghdad, Baghdad, Iraq.

³Department of Obstetrics & Gynecology, Al-Elwiya Maternity Teaching Hospital. Baghdad, Iraq.

ABSTRACT

Objective: to evaluate the value of ultrasonic fetal thalamic echogenicity and epiphyseal ossification centers of femur and tibia as signs of fetal lung maturity.

Methods: one hundred pregnant women, at their 34-42 weeks of gestation were included in this prospective study. Ultrasound examination of biparietal diameter, echogenicity of the thalamus, ossification centers of distal femur epiphyses (DFE) and proximal tibia epiphyses (PTE), amniotic fluid vernix and placental changes were performed. The outcome measures were fetal weight, Apgar score at 1 & 5 minutes, admission to neonatal intensive unit & duration, and signs of respiratory distress syndrome (RDS).

Results: the presence of PTE by ultrasound as sign of fetal lung maturity had a higher specificity, accuracy, and positive predictive value than DFE and thalamic echogenicity (91.7% versus 75% and 50% for specificity), (95% versus 92.0 and 77.0% for accuracy) and (98.8% versus 93.5% and 95.8% for PPV respectively). The sensitivity of PTE is 95.5% which is lower than DFE (97.7%) but higher than the thalamic echogenicity (77.3%).

Conclusion: the use of thalamic echogenicity and epiphyseal ossification centers in the distal femur and proximal tibia by ultrasound were valuable for a more accurate assessment of fetal lung maturity.

Keywords: fetal lung maturity; ultrasonic thalamic echogenicity; ossification centers of femur and tibia.

SOMMARIO

Obiettivo: valutare il valore dell'echogenicità talamica ultrasonica fetale e dei centri di ossificazione epifisaria del femore e della tibia come segni di maturità polmonare fetale.

Metodi: 100 donne in gravidanza, tra le 34 e 42 settimane, sono state incluse in questo studio prospettico. Sono stati effettuati esami ecografici del diametro biparietale, ecogenicità del talamo, centri di ossificazione delle epifisi del femore distale (DFE) e epifisi della tibia prossimale (PTE), vernice caseosa nel liquido amniotico e cambiamenti della placenta. Le misure di outcome erano peso fetale, punteggio di Apgar a 1 & 5 minuti, ammissione all'unità intensiva neonatale e durata e segni di sindrome da distress respiratorio (RDS).

Risultati: la presenza di PTE mediante ultrasuoni come segno di maturità polmonare fetale aveva una specificità, accuratezza e un valore predittivo positivo superiori a DFE ed ecogenicità talamica (91,7% contro 75% e 50% per specificità), (95% versus 92,0 e 77,0 % per precisione) e (98,8% contro 93,5% e 95,8% per PPV rispettivamente). La sensibilità della PTE è del 95,5% inferiore a quella del DFE (97,7%) ma superiore all'ecogenicità talamica (77,3%).

Conclusioni: l'uso di ecogenicità talamica e centri di ossificazione epifisaria nel femore distale e tibia prossimale mediante ultrasuoni sono utili per una valutazione più accurata della maturità polmonare fetale.

Corresponding Author: Qays A. Hassan
qtimeme@yahoo.com

Copyright 2018, Partner-Graf srl, Prato
DOI: 10.14660/2385-0868-99

INTRODUCTION

Respiratory distress syndrome (RDS), formerly known as hyaline membrane disease, is the most common cause of respiratory distress in preterm infants because lung immaturity is associated with inadequate production of pulmonary surfactant. RDS may be prevented, or its severity decreased with the use of antenatal steroid therapy, early administration of positive airway pressure and, in some cases, exogenous surfactant therapy⁽¹⁾.

Since the early days of ultrasound used for gestational age calculation, it was evident that ultrasound dating is less accurate after 34 weeks of gestation with a standard deviation of about \pm two weeks^(2,3). This fact pushed many researchers in the obstetrical field to use other biometric variables as a substitute to improving ultrasound dating late in the third trimester and to decide fetal maturity by assessment of different parameters including the placenta grades, biparietal diameter (BPD), epiphyseal ossification centre (EOC), thalamic echogenicity and amniotic fluid vernix^(4,5,6).

Fetal skeletal bones become visible with ultrasound only when they are calcified. While the primary ossification center develops early in pregnancy, the secondary ossification center forms in late pregnancy and early neonatal life⁽⁷⁾. The secondary ossification centers are hypoechogenic structures during intrauterine life. Only the secondary ossification centers within the epiphyseal cartilage of the proximal tibia, distal femur, and occasionally, the proximal humerus appear prenatally⁽⁸⁾. Researchers have investigated the time of appearance of the EOCs of fetal peripheral long bones (femur, tibia, and humerus) as an extra parameter⁽⁹⁾. Ultrasonographic detection of lower and upper limb EOC allows the prediction of gestational age throughout the third trimester of pregnancy with a high degree of certainty⁽⁸⁾. The most central cells of the cartilage in the epiphyses of the distal femur and the proximal tibia begin to ossify during the third trimester of pregnancy⁽⁸⁾.

Some studies reported that the fetal thalamus showed significant changes of echogenicity late in pregnancy which may have a place in assessing fetal maturity⁽⁹⁾.

In the second and third trimesters, estimation of gestational age is accomplished by measuring the BPD. BPD of at least 9.2 cm will undoubtedly predict the lack of RDS in uncomplicated gestations. The BPD is less reliable in determining gestational age when there are variations in skull shape, such as dolichocephaly or brachycephaly⁽¹⁰⁾.

Vernix caseosa is an oil-rich aggregate

substance that is observed on the fetal surface throughout the 3rd trimester of gestation. While the pregnancy advances, the quantity of squalene in the vernix raises opposed to cholesterol which in turn minimizes the adhesion of the vernix to the fetal surface. Next, the vernix will pass from the fetal surface into the amniotic fluid⁽¹⁰⁾. Many studies have been concluded that the amniotic fluid turbidity correlates well with the lung maturity as well as the complete maturity of the fetus^(11,12).

Ultrasonically diagnosed maturity changes in the placenta, grades 0 to III, have been shown to correlate with fetal lung maturity⁽¹³⁾. In an uncomplicated term pregnancy, fetal pulmonary maturation can be suggested with grade III placenta⁽¹⁰⁾.

The purpose of this study was to evaluate the value of fetal thalamic echogenicity and epiphyseal ossification center of fetal femur and tibia by ultrasound in comparison with other parameters that are used in our daily practice as signs of fetal lung maturity reported by ultrasound.

MATERIALS AND METHODS

This was a prospective longitudinal study conducted at Al-Elwiya Maternity Teaching Hospital, Baghdad, Iraq between April 2015 and August 2017. Ethical clearance for the study was obtained from the local thesis committee of the hospital (research project ID:132/16). Informed (verbal and written) consent for all participated women was obtained.

Inclusion criteria included all women having uncomplicated singleton pregnancy with a viable fetus and regular fetal surveillance. Women had to be sure of their last menstrual period date and to have had this date reinforced by ultrasonography during the first trimester of gestation.

Exclusion criteria included cases with multiple gestations, fetal malformations, complicated pregnancy (hypertension, diabetes, etc...), intrauterine growth restriction or macrosomic fetuses, suboptimal fetal position in which epiphyses could not be observed, antepartum hemorrhage or presence of meconium-stained fluid, and smoker pregnant. All mothers were examined by ultrasound prenatally for fetal maturity signs and the neonates after delivery. Only 5 cases were loosed in the follow-up period and were excluded from this study.

The women who fulfill these criteria mentioned earlier were enrolled in this study, and they were

100 pregnant women, 17 to 40 years old at 34 to 42 completed weeks of gestation. In the current study, women were delivered by cesarean section under spinal anesthesia to omit the effect of general anesthesia on the neonate.

Ultrasound examination was done with convex transducers frequency of 3.5 MHZ (Braun, U.K.) at the radiology department for an obstetric ultrasound scan on the same day of their delivery. The ultrasound examination was conducted by the same ultrasonographer to decrease the intra-observer variation. Ultrasound examination included the following criteria for fetal lung maturity:

- Thalamic density at the level of the BPD, on each side of the third ventricle, the density is divided to either echogenic if similar to the rest of the brain tissue in echogenicity, or echolucent if it was less-echogenic to the rest of the brain tissue.
- Ossification centers in distal femoral epiphysis (DFE), was identified by visualizing the distal femur epiphysis as a slit-like ovoid or globular echogenic structure centrally placed within the hypoechogenic epiphyseal cartilage of the femur at its distal extremity. Its exact identification was made by guiding the transducer along the largest axis of the femoral diaphysis avoiding oblique sectioning.
- Proximal tibial epiphysis (PTE), that was also an echogenic structure adjacent to the tibial head and measured similarly. Measurements of EOC were obtained in an axial plane from outer to outer margins along the medial-lateral surfaces of the epiphysis. Care was always taken not to mistake the ossification centers for the echogenic material within the intercondylar notch, or even for the patella or transversal sectioning of the long bones near the epiphyses.

Besides, the following criteria that predict fetal lung maturity also were assessed:

- Placental changes according to the Grannunm classification,
- BPD which was measured in millimeters, and
- Vernix in the amniotic fluid.

The pediatrician examined each neonate for the following fetal outcomes: fetal sex, weight, APGAR score at one and five minutes, signs of a respiratory problem, admission to the neonatal intensive care unit (NICU) and followed by

pediatrician for the duration of hospitalization, and any adverse neonatal morbidity or mortality up to discharge.

The six ultrasound parameters for assessing fetal pulmonary maturity (BPD, placental changes, amniotic fluid vernix, thalamus and ossification center of distal femoral and proximal tibial epiphyses) were collected & correlated to the neonatal outcome & subjected to comparison.

RESULTS

A total of 100 women were included in this study. The mean maternal age was 27.6 ± 5.4 (range: 17 - 40) years, mean gestational age 37.06 ± 2.0 (range: 34 - 42) weeks and by ultrasound (U/S) 37.05 ± 2.02 (range: 34 - 42) weeks. Regarding the occupation; the majority of the participant women were housewives; (96%), 3% were teachers and only one was a student. Nulliparous was 17%, and the remaining 83 women had one or more parity. History of abortion was reported in 16 women. All these findings were shown in **Table 1**.

Table 1.
Demographic characteristics of the studied group.

		No.
Maternal age (year)	Mean \pm SD	27.6 \pm 5.4
	Range	17 - 40
Gestational age (week)	Mean \pm SD	37.06 \pm 2.0
	Range	34 - 42
Gestational age by US (week)	Mean \pm SD	37.05 \pm 2.02
	Range	34 - 42
Occupation	Housewife n (%)	96 (96.0)
	Other	4 (4.0)
Gravidity	1 - 2	38 (38.0)
	3 - 4	45 (45.0)
	≥ 5	17 (17.0)
Parity	Nulliparous	17 (17.0)
	One	23 (23.0)
	Two	32 (32.0)
	Three	17 (17.0)
	≥ 4	11 (11.0)
History of previous abortion		16 (16.0)

US: Ultrasound, SD: Standard deviation

Table 2 shows the characteristics of the neonates of the participant women. Apgar score at 1 min. was < 7 in 45 neonates and ≥ 7 in the remaining 55. At 5 min, 33 neonates still with Apgar score of <7 while 67 neonates showed Apgar score ≥7. On the other hand, 41% needed to be admitted to the neonatal intensive care unit (NICU) for different durations and different causes. 63.4% admitted for < 24 hours, 22% for 24–48 hours and 14.6% admitted to the NICU for > 48 hours. Additionally, none of the neonates reported additional co-morbidities up to discharge.

The clinical assessment of the neonates revealed RDS in 12 of them (12%), while the remaining 88 (88%) neonates with no RDS. The RDS status was used as an indicator for the fetal lung maturity, those with RDS considered to have immature fetal lung and those with no RDS to have mature fetal lung

For prediction of lung maturity, fetal tibial epiphysis shows statistically significant P value (< 0.001). Eighty-six ladies with positive fetal femoral epiphyses have no RDS which indicates statistical significance for lung maturity prediction (P < 0.001). Echogenic thalami were reported in 71 women; 68 had no RDS and 3 with RDS. Thalamic echogenicity revealed statistical significance for detection of fetal lung maturity (P = 0.001). RDS

status against biparietal diameter categories (> 9.2 and ≤ 9.2) (P = 0.021) which is statistically significant. Amniotic fluid vernix as a predictor of fetal lung maturity had P < 0.001 as shown in **Table 3**.

Table 2.
Characteristics of the neonates.

Variable	No.	%	
Apgar score at 1 min	< 7	45	45.0
	≥ 7	55	55.0
Apgar score at 5 min	< 7	33	33.0
	≥ 7	67	67.0
Admission to the NICU		41	41.0
Duration of stay in the NICU	< 24 hr	26	63.4
	24 - 48 hr	9	22.0
	> 48 hr	6	14.6

NICU: Neonatal intensive care unit

Table 3.
Results of ultrasound parameters in the prediction of fetal lung maturity.

Ultrasound parameter	Ultrasound finding	No RDS	RDS	p value
Fetal tibia epiphysis	Positive	84	1	<0.001
	Negative	4	11	
Fetal femur epiphysis	Positive	86	6	<0.001
	Negative	2	6	
Thalamic echogenicity	Echogenic	68	3	0.001
	Echolucent	20	9	
Biparietal diameter	>9.2 cm	50	2	0.021
	≤9.2 cm	38	10	
Amniotic fluid vernix	Positive	56	4	<0.001
	Negative	32	8	
Placenta grading	Grade II and III	53	3	0.045
	Grade 0 and I	35	9	

RDS: Respiratory distress syndrome

The comparison matrix of the results of the validity tests of the six parameters was shown in **Table 4**. According to these comparisons, it had been noticed that the fetal tibial epiphysis was highly sensitive (95.5%), highly specific (91.7%) and had the highest accuracy (95%) with excellent PPV (98.8%) and good NPV (73.3%). Fetal femoral epiphysis was also highly sensitive (97.7%) but low specific (50.0%) and good accuracy (92.0%). Thalamic echogenicity was low sensitive (77.3%) and good specific (75.0%), with moderate accuracy (77.0%), high PPV (95.8%) and low NPV (31.0%).

Regarding other parameters (amniotic fluid vernix, BPD and placenta grading), the sensitivity, accuracy, and NPV were lower than the previous three parameters, while they had high PPV. Furthermore, the specificity of these parameters was lower than fetal tibial epiphysis but higher than fetal femoral epiphysis.

For more precise assessment of the validity of these parameters as predictors of fetal lung maturity, further analysis was performed by using the receiver operating characteristics curve (ROC curve) (**Figure 1**). The ROC curve revealed that fetal tibial epiphysis was the best predictor for fetal lung maturity with an area under the curve (AUC) of (0.93), followed by fetal femoral epiphysis (AUC = 0.75), thalamic echogenicity

(AUC=0.76), BPD (AUC=0.70), amniotic fluid vernix (AUC=0.65), and placenta grading with the lower AUC of (0.61).

The correlation of ultrasound results and RDS at different gestational age was shown in **Table 5**.

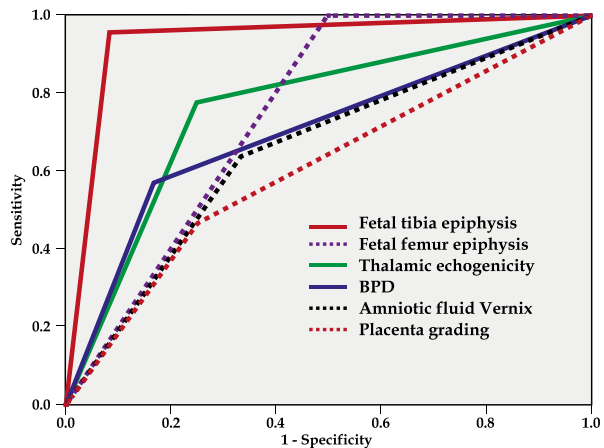


Figure 1. Receiver operation characteristics (ROC) curve for prediction of fetal lung maturity.

Table 4. Validity tests for prediction of lung maturity of the 100 neonates.

Parameter	Sensitivity	Specificity	Accuracy	PPV	NPV
Fetal tibia epiphysis	95.5%	91.7%	95.0%	98.8%	73.3%
Fetal femur epiphysis	97.7%	50.0%	92.0%	93.5%	75.0%
Thalamic echogenicity	77.3%	75.0%	77.0%	95.8%	31.0%
Amniotic fluid vernix	63.6%	66.7%	64.0%	93.3%	20.0%
Biparietal diameter	56.8%	83.3%	60.0%	96.2%	20.8%
Placental grading	60.2%	75.0%	62.0%	94.6%	20.5%

PPV: Positive predictive value, NPV: Negative predictive value

Table 5.
Correlation between US parameters results and RDS according to gestational age.

Ultrasound parameters		Gestational age							
		34-35 (n=30)		36-37 (n=30)		38 - 39 (n=30)		40-42 (n=10)	
		No RDS	RDS	No RDS	RDS	No RDS	RDS	No RDS	RDS
Fetal tibia epiphysis	Positive	22	0	23	1	29	0	10	0
	Negative	2	6	2	4	0	1	0	0
Fetal femur epiphysis	Positive	24	2	25	3	29	1	10	0
	Negative	0	4	0	2	0	0	0	0
Thalamic echogenicity	Positive	6	0	11	1	15	1	7	0
	Negative	18	6	14	4	14	0	3	0
Biparietal diameter	>9.2 cm	2	0	14	1	25	1	9	0
	<9.2cm	22	6	11	4	4	0	1	0
Amniotic fluid Vernix	Positive	7	0	17	3	24	1	8	0
	Negative	17	6	8	2	5	0	2	0
Placental grading	Grade II&III	4	1	12	2	17	0	8	0
	Grade 0&I	20	5	13	3	12	1	2	0

RDS: Respiratory distress syndrome

DISCUSSION

The present study was designed to evaluate the predictive values and validity of measuring some fetal parameters by ultrasound as markers of fetal lung maturity. These parameters include fetal thalamic echogenicity, epiphyseal ossification centers of femur and tibia, placenta grading, BPD and amniotic fluid vernix.

The current study reported that more than half of the delivered neonates (55%) had an Apgar score at 1 minute of < 7, While only 33% at 5 minutes. From another point of view, RDS was used as an indicator in our study for fetal lung immaturity and showed only 12% RDS which decreased with advanced gestational age. This result agrees with the study of Hibbard et al.(14) who gave comparable outcomes and found an incidence of 10.5% for infants born at 34 - 36 weeks gestation versus 0.3% at 38 weeks. Other studies showed a lower incidence of RDS such as Edwards et al.(15) which documented that RDS occurs in up to 7% of newborn infants and Ghafoor et al.(16) which reported an incidence rate of RDS 3.7% among neonates at 36 weeks of gestation.

The higher incidence of RDS might be due to the inclusion of women at late preterm gestational age; where 31% of the study group were at (34 -36) weeks gestation and this might increase the incidence of RDS. However, there is a wide variation in the published incidence figures of RDS worldwide despite the progress made in perinatal care.

In our study, RDS was cross-tabulated against the sonographic finding of each parameter. Hence, the fetal tibia epiphysis was the best predictor compared to other five parameters (with 95.5%, 91.7% and 95% for sensitivity, specificity, and accuracy respectively), followed by fetal femur epiphysis (with sensitivity of 97.7%, specificity 50% and accuracy of 92%).

Mahony et al.(17) assessed sonographic epiphyseal ossification centers in the assessment of fetal lung maturity in correlation with the amniocentesis lung profile. They found that proximal tibia epiphysis had an accuracy of positive predicting a mature amniocentesis lung profile of (100%), and specificity of (100%),

while sensitivity and accuracy of prediction of an immature amniocentesis lung profile were low (22-25%) for the same epiphyseal parameters. These data suggested that antenatal visualization and measurement of the epiphyseal ossification of the fetal knee and shoulder may help to identify fetuses that would have a mature amniocentesis lung profile. Interestingly, fetuses in which both distal femur epiphysis and proximal tibia epiphysis were positive, yielded positive results and higher accuracy⁽¹⁷⁾.

Furthermore, some investigators used EOC as markers of fetal gestational age and indirectly predict fetal maturity^(18,19). A study done by Ahmad T et al.⁽²⁰⁾ found that sonographic evaluation of distal femoral and proximal tibial epiphyseal centers can be practiced as sufficient markers for the calculation of gestational age during the third trimester. Another study by Tabsh KM⁽²¹⁾ found that ossification centers about the fetal knee (DFE and PTE) as measured by ultrasound correlate well with amniotic fluid lecithin: sphingomyelin ratio.

Nonetheless, several precautions should be taken; while the presence of these centers may be helpful in determining fetal lung maturity, their absence does not indicate that a fetus necessarily does not have mature lung. Additionally, adjacent structures to the cartilaginous centers should not be misinterpreted as the epiphyseal centers. Moreover, in complicated pregnancies, the identification of DFE of any size may not correlate with fetal lung maturity⁽¹⁷⁾.

In our study, it was shown that sensitivity; specificity and accuracy of fetal thalamic echogenicity in the prediction of fetal lung maturity are 77.3%, 75.0%, and 77.0% respectively. In our daily practice, we observed that thalamic density increased with gestational age, so the present study was conducted to evaluate this sign and EOC and attempt to present them as a pointer for lung maturity.

At 2001, Faris Anwer⁽⁹⁾ did a prospective, pioneer study at the private antenatal clinic to determine the fetal thalamus ultrasonic change with increasing age and concluded by that study that fetal thalamus showed statistically significant differences of echogenicity late in pregnancy which may have a place in assessing fetal maturity.

Later other study done by Faris A et al.⁽¹⁰⁾ showed that sensitivity and specificity of fetal thalamic echogenicity in the prediction of fetal lung maturity are: 63.33%, 86.53% respectively and those results are near to our results.

Our study showed that BPD > 9.2 cm correlates

with fetal lung maturity. In other research done by Slocum WA et al.⁽²²⁾, a threshold BPD of greater than or equal to 9.2 cm in all parturient who underwent elective repeat cesarean delivery was associated with no hyaline membrane disease (HMD). Additionally, Prakash et al.⁽²³⁾ mentioned that sonographically determined parameters: fetal biparietal diameter and placental grading, have been related to fetal maturity, with accuracy ranging from 78% to 100%.

Regarding amniotic fluid vernix, our study revealed the sensitivity of 63.6% and specificity of 66.7% for prediction of fetal lung maturity. In another study⁽¹⁰⁾, also it found that amniotic fluid vernix had a role in the prediction of fetal lung maturity with a sensitivity of 86.66% and specificity is 48.7%. Other studies recorded different values. Ram SHS and Ram S.⁽²⁴⁾ assessed the amniotic fluid particles and its predictive value for fetal lung maturity and found a sensitivity of (85.74%) which was higher than our finding and PPV of (66.67%) lower than ours (93.3%) in the prediction of RDS. This variation might be attributed to the difference in the used technique (amniocentesis versus ultrasound) or inter-observer variations.

Shweni and Moodley⁽²⁵⁾ did a study documented that all the fetuses with placental grade II and III had achieved lung maturity which suggested that placental grading could replace estimation of lecithin /sphingomyelin (L/S) ratio and reduce the number of amniocenteses needed. Other researchers in this topic had projected uncertainty on the reliability of placental grading as a predictor of fetal lung maturity, and the subject has become doubtful for many causes including the presence of complications like hypertension, diabetes mellitus or Rh iso-immune disease⁽¹⁰⁾.

Also, Loret de Mola JR et al.⁽²⁶⁾ found that placental grade III had sensitivity 64% and specificity 98% for mature amniocentesis, but in our study placental maturity had sensitivity 60.2% and specificity 75.0% in the prediction of fetal lung maturity. An amniocentesis would then be reserved for patients uncertain of their dates, those with complicated pregnancies, and those with grade 1 or 0 placentae⁽²⁵⁾.

In conclusion, our study shows that ultrasound assessment for fetal lung maturity is a useful non-invasive procedure with good predictive values and accuracy. All the six evaluated ultrasonic parameters could be considered as predictors for fetal lung maturity with different extent in their performance. The ultrasonic identification of the ossification centers of the proximal tibia showed

the best performance in predicting the fetal lung maturity, followed by distal femur epiphysis and thalamic echogenicity and then the other three parameters: biparietal diameter, amniotic fluid vernix, and placental grading.

REFERENCES

- 1) Sakonidou S, Dhaliwal J. **The management of neonatal respiratory distress syndrome in preterm infants** (European Consensus Guidelines-2013 update). Arch Dis Child Educ Pract Ed 2015;100:257.
- 2) Leung TN, Pang MW, Daljit SS, Leung TY, Poon CF, Wong SM, et al. **Fetal biometry in ethnic Chinese: biparietal diameter, head circumference, abdominal circumference and femur length.** Ultrasound Obstet Gynecol. 2008;31:321-7.
- 3) Salomon LJ, Duyme M, Crequat J, Brodaty G, Talmant C, Fries N, et al. French fetal biometry: reference equations and comparison with other charts. Ultrasound Obstet Gynecol. 2006;28:193
- 4) Gast AS, Sohn C BG. **Ultrasound diagnosis of fetal lung maturity.** Zentralbl Gynakol J. 1995;117:138-43.
- 5) Guoyang Luo, Errol R Norwitz. **Revisiting Amniocentesis for Fetal Lung Maturity After 36 Weeks' Gestation.** Rev Obstet Gynecol. 2008;1:61-8.
- 6) Prakash B, Ramakrishnan A, Suresh S, Chow TWP. **Fetal lung maturity analysis using ultrasound image features.** IEEE Trans Inf Technol Biomed. 2002;6:38-45.
- 7) O' Rahilly R, Gardner E. **The initial appearance of ossification in stage human embryos.** Am. J. Ant.1972;134: 291-301.
- 8) Chinn DH, Bolding DB, Callen PW, Gross BH, Filly RA. **Ultrasonographic identification of fetal lower extremity epiphyseal ossification centers.** Radiology. 1983;147:815-8.
- 9) Faris Anwer. **Fetal thalamus echogenicity changes with increasing fetal age.** Iraqi Med J. 2001;50:396-400.
- 10) Faris A. Rasheed, Zahraa' M. Al-Sattam, Saad A. Hussain. **Evaluation of thalamus echogenicity by ultrasound as a marker of fetal lung maturity.** Open J Obstet Gynecol. 2012;2:270-5.
- 11) Kars B, Karsidag A, Buyukbayrak E, Telatar B, Turan C, Unal O. **Evaluation of fetal lung maturity by turbidity testing and tap test.** J Turk Soc Obstet Gynecol 2011;8:25- 31
- 12) Rao NYL, Isuapalli V, Samyukta Ila S. **Amniotic Fluid Optical Density (AFOD) correlates with the lung maturity as well as complete maturity of the fetus - A clinical observational study.** Int Arch Integ Med. 2015;2:30-7.
- 13) Deopa D, Ramesh CSB, Dubey K, Aneja S. **Comparison of placental grading by ultrasonographic study in normal and high risk pregnancy in north indian populations.** J Anat. Soc India. 2011;60:31-6.
- 14) Hibbard JU, Wilkins I, Sun L, Gregory K, Haberman S, Hoffman M, et al. **Respiratory Morbidity in Late**

CONFLICTS OF INTEREST

The authors declare that they have no conflicts of interest.

- 15) Edwards MO, Kotecha SJ, Kotecha S. **Respiratory Distress of the Term Newborn Infant.** Paediatr Respir Rev. 2013;14:29-36.
- 16) Ghafoor T, Mahmud S, Ali S, Dogar SA. **Incidence of respiratory distress syndrome.** J Coll Physicians Surg Pak. 2003;13:271-3.
- 17) Mahony BS, Bowie JD, Killam a P, Kay HH, Cooper C. **Epiphyseal ossification centers in the assessment of fetal maturity: sonographic correlation with the amniocentesis lung profile.** Radiology. 1986;159:521-4
- 18) Donne HD, Faundes A, Tristao EG, de Sousa MH, Urbanetz AA. **Sonographic identification and measurement of the epiphyseal ossification centers as markers of fetal gestational age.** J Clin Ultrasound. 2005;33:394-400.
- 19) Reenu K, Amod KY, Kishwore B, Haritha KN and Rajni S. **Ossification Centers of distal femur, proximal tibia and proximal humerus as tool for estimating gestational age of fetus in third trimester of pregnancy in west indian population: an ultrasonographic study.** Int J Basic App Med Sci. 2015;5:316-21.
- 20) Ahmad T, Siddiqi IH. **Ultrasonographic assessment of Gestational age with distal femoral and proximal tibial ossification centers.** Pakistan Postgrad Med J. 2001;12:170-2.
- 21) Tabsh KM. **Correlation of ultrasonic epiphyseal centers and the lecithin: sphingomyelin ratio.** Obstet Gynecol. 1984;64:92-6.
- 22) Slocum WA, Martin JN, Whit Worth NS, Morrison JC. **Third trimester biparietal diameter as a predictor of fetal lung maturity.** Am J perinatal. 1987;4:266-70.
- 23) Prakash KN, Ramakrishnan a G, Suresh S, Chow TW. **An investigation into the feasibility of fetal lung maturity prediction using statistical textural features.** Ultrason Imaging. 2001;23:39-54.
- 24) Ram SHS, Ram S. **Role of Echogenic Amniotic Fluid Particles and Optical Density in prediction of Respiratory Distress Syndrome and Labor.** Inter J Med Update. 2010;5:3-11.
- 25) Shweni PM, Moodley SC. **Placental grading by ultrasonography as an index of fetal maturity. Its application to the problem of elective caesarean section.** S Afr Med J. 1986;70:525-8.
- 26) Loret de Mola JR, Judge N, Entsminger C, DeViney M, Muise KL, Duchon MA. **Indirect prediction of fetal lung maturity. Value of ultrasonographic colonic and placental grading.** J Reprod Med. 1998;43:898-902.