

# Intramural ectopic pregnancy: report of a singular case of intramural pregnancy

Maria Vittoria Capogna<sup>1</sup>, Andrea Costantini<sup>2</sup>, Nicola Santomarco<sup>2</sup>, Emilio Piccione<sup>1</sup>, Michelangelo Boninfante<sup>2</sup>

<sup>1</sup> Section of Gynecology and Obstetrics, Academic Department of Biomedicine and Prevention, University Tor Vergata, Rome, Italy

<sup>2</sup> Division of Gynecology and Obstetrics, "M.G. Vannini" Hospital, Rome, Italy

## ABSTRACT

### Intramural ectopic pregnancy: a case report

A rare condition of ectopic pregnancy, with potential severe consequences if not diagnosed and treated early, is the intramural one. Here, we report the case of a woman with intramural pregnancy. The first suspicion of the presence of such a condition emerged while doing a transvaginal sonography, after which it was decided to excise the mass in order to confirm its nature histologically. The gestational sac was then excised via laparotomy and the following histological examination proved our hypothesis of having come across an intramural pregnancy.

Key words: Ectopic pregnancy, intramural ectopic pregnancy, diagnosis and treatment.

## SOMMARIO

### Gravidanza ectopica intramurale: caso clinico

Una condizione rara di gravidanza ectopica è rappresentata dalla gravidanza intramurale, che se non diagnosticata e trattata precocemente può comportare diverse complicanze. Qui, noi riportiamo il caso di una donna con una gravidanza intramurale. Il primo sospetto della presenza di questa condizione è emerso durante l'esecuzione dell'ecografia pelvica transvaginale, a seguito del quale si è deciso di asportare la massa al fine di confermarne istologicamente la sua natura. Il sacco gestazionale, asportato chirurgicamente per via laparotomica e successivamente esaminato istologicamente, ha confermato la nostra ipotesi deponente per gravidanza intramurale.

Parole chiave: Gravidanza ectopica, gravidanza ectopica intramurale, diagnosi e trattamento.

## INTRODUCTION

Intramural pregnancy is extremely rare; as a matter of fact, it represents less than 1% of all the ectopic pregnancies<sup>(1)</sup>. It was described for the first time in 1993<sup>(2)</sup> and there have been only 53 cases reported in the scientific literature until now<sup>(3)</sup>. This condition has been defined as a pregnancy located within the uterine wall, completely surrounded by myometrium and separated from the uterine cavity and fallopian tube<sup>(4)</sup>.

Its etio-pathogenesis has not been completely defined yet. As regards it, there are many different hypothesis, such as: lytic activity of the syncytiotrophoblast and defective decidualization, that allows the conceptus either to penetrate the myometrium, or to implant in the serosa after an outward migration<sup>(5)</sup>; previous uterine trauma (such as previous dilatation and curettage, caesarean section, or myomectomy), which result in a sinus tract within the endometrium<sup>(6)</sup>; adenomyosis<sup>(7)</sup> or embryo transfer in the assisted reproduction technique which result in the creation of a false passage<sup>(5)</sup>.

Intramural pregnancy is something worrying because it may lead to uterine rupture and life-threatening hemorrhage, which inevitably conduct

to an undesirable hysterectomy. This is why, early diagnosis and treatment of this condition can avoid serious complications; nevertheless, because of the small number of cases reported, there isn't an universal treatment modality yet. We reported a case of fundus intramural pregnancy in a woman with previous gynecological surgeries.

## CASE PRESENTATION

A 37 years old primigravida was referred to our hospital (Vannini Hospital) 10 weeks + 2 days after her last menstrual period, sent by her attending physician with the diagnosis of threatened miscarriage. The woman had no history neither of abortion or gestational trophoblastic disease, but she had undergone gynecological surgeries such as:

- laparotomic myomectomy in 2002;
- hysteroscopy for Asherman's syndrome in 2008;
- laparoscopic myomectomy in 2012.

The obstetric examination showed no vaginal bleeding, no uterine dilatation, neither uterine contractions or abdominal pain and tenderness.

The Patient was hemodynamically stable. She was bringing with her the results of the dosage of serum B-human chorionic gonadotropin (b-HCG), that she had done 15 days before,

Correspondence to: maria.vittoria.cap77@alice.it

which showed a level of 57.000 UI/ml. Obstetric ultrasound showed a gestational chamber of mm 33x20, placed in the right lateral part of the uterine fundus and inside of which, weak hyperechogenous signals were found. Those echoes had to be referred to a yolk sac, which apparently was not implanted inside the uterine cavity, but in the context of the myometrial wall (Figure 1). That evidence rose the suspicion of either an angular or an intramural pregnancy.

This is why it was decided to do an ultrasound-guided revision of the uterine cavity.

Unfortunately, during this procedure, it was not possible to reach the gestational chamber, which was dislocated on the uterine fundus near the right tubal corner, as shown by the ultrasound.

So it was decided to introduce a diagnostic hysteroscope, with which it was possible to visualize both the uterine cavity and the left tubal hole, while on the right side, just above the tubal corner, the uterine cavity appeared as imprinted by a swelling.

It was then decided to do a diagnostic laparoscopy, that showed a round, highly vascularized swelling, the maximum diameter of which was about 2-3 cm, placed in the right side of the uterine fundus and extended up to the emergence of the salpinx (most likely, in the location of the previous myomectomy).

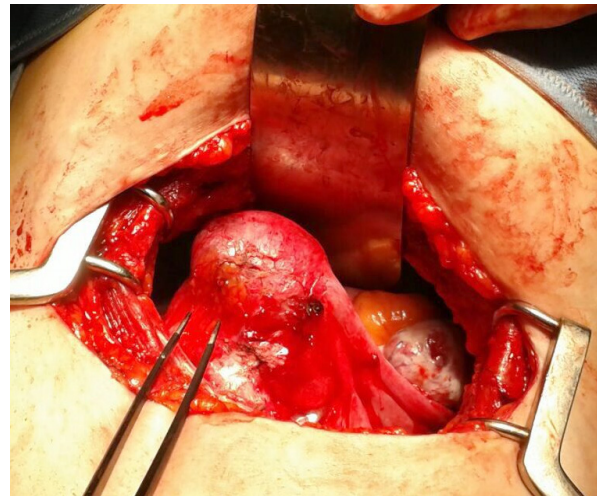
Considering both the concrete risk of bleeding and the presence of adhesions, visualized in laparoscopy and which limited the mobilization of the uterus by fixing the anterior uterine wall to the bladder, it was decided to perform a laparotomy.

During that operation, the adhesions were lysed, so that the anterior uterine wall was

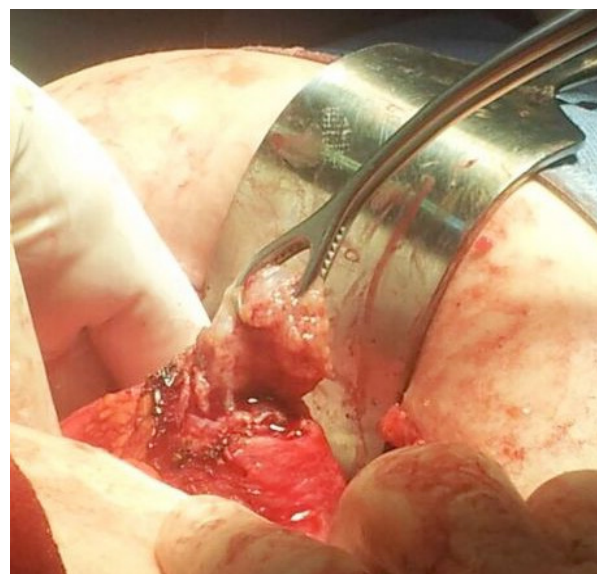
released. After that, the swelling was incised (Figure 2) and the underlying gestational chamber and trophoblast were excised (Figure 3). It was then performed a revision of the implant location after which the uterine breach was closed with detached stitches made of vicryl.

The postoperative course was regular.

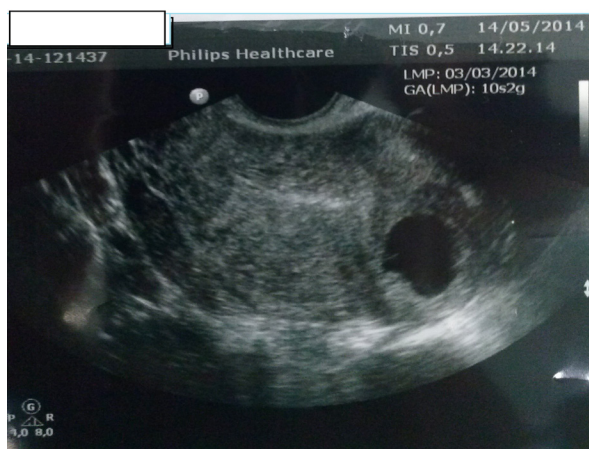During the first, the second and the fifth postoperative days, dosages of serum b-HCG were done and they showed a gradual decrease in its values (respectively 3144UI/ml, 1622 UI/ml and 486 UI/ml).



**Figure 2.**  
*Intraoperative view: highly vascularized swelling in the right side of the uterine fundus.*



**Figure 3.**  
*Intraoperative view: removal of gestational chamber and trophoblast.*



**Figure 1.**  
*Pre-operative transvaginal ultrasound scan reveals a gestational chamber with weak hyperechogenous signals in the right lateral part of the uterine fundus.*

In the 6<sup>th</sup> postoperative day, the patient was dismissed in good health conditions.

Fifteen days after discharge, the first medical follow-up visit was performed and in that occasion the patient was suggested to repeat the dosage of b-HCG as long as they were not reset to zero.

In the meantime, the histological examination had confirmed the presence of chorionic villi in the myometrium.

## DISCUSSION

Intramural pregnancy is extremely rare, but it may result in serious morbidity mainly due to hemorrhage resulting from a uterine rupture; for this reason, early diagnosis is necessary<sup>(4)</sup>. As said before, the etiology of this condition, is still not known, but, among the risk factors that have been described until now, probably, the most important in our case consists in the two previous myomectomies, which promoted the implantation on the surgical scar.

Early diagnosis of intramural pregnancy has become possible thanks to the progresses in the sonography technique. As a matter of fact, sonography is the most common instrument used for the diagnosis of this condition. The transvaginal sonographic findings which are considered as the typical sonographic portrayals of an intramural pregnancy, include a gestational sac inside the myometrium completely surrounded by it and no gestational sac in the endometrial cavity<sup>(8)</sup>. In our case, transvaginal sonography showed a gestational sac which was not in the uterine cavity and our doubt was between an intramural or an angular pregnancy.

Lee et al.<sup>(9)</sup> described some sonographic characteristics, which can help us in distinguishing an intramural from interstitial pregnancy. As a matter of fact, intramural pregnancy appears as a gestational chamber, with or without a yolk sac, inside the myometrium. Whereas, interstitial pregnancy is characterized by:

- the prosecution of a thin layer of myometrium around the gestational sac
- the visualization of the "interstitial line" which consists in a line located between the endometrial cavity and the gestational sac and that sonographically appears as echogenic.

Other examinations which can be useful to diagnose an intramural pregnancy are: Color Doppler imaging, that shows an increased

peritrophoblastic blood flow<sup>(10)</sup>; 3D sonography, which, on one hand, allows to define the exact localization of the gestational sac and to distinguish it from an interstitial ectopic pregnancy, and, on the other hand, thanks to the availability of multiple scan planes, can help in defining the relationship between the gestational sac and the endometrial cavity<sup>(11)</sup>. Moreover, it must be considered the importance of magnetic resonance imaging (MRI) that, thanks to availability of multiple scan planes, can help in defining the relationship between the gestational sac and the endometrial cavity. A trabecular pattern of heterogeneous signal intensity in the mass is observed in T2-weighted images, and enhanced treelike solid components are shown in contrast-enhanced T1-weighted images<sup>(12)</sup>.

An early diagnosis of intramural ectopic pregnancy permits a conservative management, which can be either medical or surgical<sup>(11)</sup>.

Methotrexate is the most commonly used drug and it may be given either locally or systemically<sup>(13)</sup>. The main surgical option is the local excision of the intramural pregnancy via laparoscopy or laparotomy<sup>(14)</sup>.

Surgical management may be considered in those patients who are at higher risk of bleeding, in case of large size of the pregnancy mass, or in patients who are hemodynamically unstable or unable to withstand a long-term follow-up if admitted a medical surgery<sup>(11)</sup>.

As a consequence of these considerations, we decided to perform an excision via laparotomy in order to better control any eventual bleeding and to preserve our patient's fertility.

## CONCLUSION

An early diagnosis and a correct treatment, in the light of either the patient's clinical conditions, the evaluation of the risk factors and the integration of the different kind of available diagnostic techniques, permit to manage this condition successfully, by avoiding radical operations such as a hysterectomy, with the result of preserving the woman's fertility. In conclusion, an early diagnosis can improve the prognosis.



## REFERENCES

- 1) Bernstein HB1, Thrall MM, Clark WB. **Expectant management of intramural ectopic pregnancy.** *Obstet Gynecol.* 2001 May;97(5 Pt 2):826-7.
- 2) Lu HF, Sheu BC, Shih JC, Chang YL, Torng PL, Huang SC. **Intramural ectopic pregnancy. Sonographic picture and its relation with adenomyosis.** *Acta Obstet Gynecol Scand.* 1997 Oct;76(9):886-9.
- 3) Kirk E1, McDonald K, Rees J, Govind A. **Intramural ectopic pregnancy: a case and review of the literature.** *Eur J Obstet Gynecol Reprod Biol.* 2013 Jun;168(2):129-33.
- 4) Wang J, Xie X. **Sonographic diagnosis of intramural pregnancy.** *J Ultrasound Med.* 2013 Dec;32(12):2215-7.
- 5) Khalifa Y1, Redgment CJ, Yazdani N, Taranissi M, Craft IL. **Intramural pregnancy following difficult embryo transfer.** *Hum Reprod.* 1994 Dec;9(12):2427-2428.
- 6) Neiger R1, Weldon K, Means N. **Intramural pregnancy in a cesarean section scar. A case report.** *J Reprod Med.* 1998 Nov;43(11):999-1001.
- 7) Karakök M1, Balat O, Sari I, Kocer NE, Erdogan R. **Early diagnosed intramural ectopic pregnancy associated with adenomyosis: report of an unusual case.** *Clin Exp Obstet Gynecol*2002;29(3):217-8.
- 8) Lin YH, Seow KM, Huang. **Rupture intramural pregnancy with low and declining - human chorionic gonadotropin levels.** *Taiwan J Obstet Gyneacol* 2005; 44:91-93.
- 9) Lee GS, Hur SY, Kown I, Shin JC, Kim SP, Kim SJ. **Diagnosis of early intramural ectopic pregnancy.** *J Clin Ultrasound.* 2005 May;33(4):190-192.
- 10) Memtsa M, Jamil A, Sebire N, Jauniaux E, Jurkovic D. **Diagnosis and management of intramural ectopic pregnancy.** *Ultrasound Obstet Gynecol.* 2013 Sep;42(3):359-62.
- 11) Ong C1, Su LL, Chia D, Choolani M, Biswas A. **Sonographic diagnosis and successful medical management of an intramural ectopic pregnancy.** *J Clin Ultrasound.* 2010 Jul;38(6):320-4.
- 12) Ko HS1, Lee Y, Lee HJ, Park IY, Chung DY, Kim SP, et al. **Sonographic and MR findings in 2 cases of intramural pregnancy treated conservatively.** *J Clin Ultrasound.* 2006 Sep;34(7):356-60.
- 13) Katano K1, Ikuta K, Matsubara H, Nishio M, Suzumori K. **A case of successful conservative chemotherapy for intramural pregnancy.** *Fertil Steril.* 1999 Oct;72(4):744-6.
- 14) Kirk E1, McDonald K, Rees J, Govind A. **Intramural ectopic pregnancy: a case and review of the literature.** *Eur J Obstet Gynecol Reprod Biol.* 2013 Jun;168(2):129-33.